

# The Value of Intravascular Ultrasound Use in Hemodialysis Arteriovenous Access

A panel of experts addresses how and why clinicians today are increasingly reaching for IVUS during AV access evaluations.



## **Bart Dolmatch, MD**

Vascular and Interventional Radiologist  
Palo Alto Medical Foundation  
Mountain View, California  
*Disclosures: Advisory board member of Bard Peripheral Vascular, Inc., Symic Inc., Bluegrass Vascular Technologies, Inc., TVA Medical, Inc.; investor in Merit Medical Systems, Inc; speakers bureau for Bard Peripheral Vascular, Inc.; co-course director for CiDA and SoDA.*



## **Jeffrey E. Hull, MD**

Chief of Vascular and Interventional Radiology  
Radiology Associates of Richmond  
Richmond Vascular Center  
Richmond, Virginia  
*Disclosures: Founder and consultant of Avenu Medical.*



## **Rick de Graaf, MD, PhD**

Interventional Radiologist  
Department of Radiology  
Maastricht University Medical Centre  
Maastricht, The Netherlands  
*Disclosures: Consultant and speaker fees from OptiMed GmbH, Bard Peripheral Vascular, Inc., TVA Medical, Inc., Philips Volcano, and Cook Medical.*



## **Edward Pavillard, DO**

Vascular Surgeon  
Phoenixville Surgery Associates  
Limerick, Pennsylvania  
*Disclosures: None.*

**A**lthough relatively stable, both catheter-based and arteriovenous (AV) hemodialysis access require care, attention, and upkeep to limit problems. The primary causative

pathology is intimal hyperplasia leading to venous stenosis, disruption in flow, and eventual thrombosis. Central venous obstruction (CVO) is common with catheter implants, which is a temporary access

and the least stable compared with AV grafts or AV fistulas.

For many clinicians, angiography remains the gold standard for visualizing problem areas, with intravascular ultrasound (IVUS) used as an adjunct modality. IVUS provides better characterization and diagnosis of stenosis/thrombus responsible for failing access and is particularly helpful in identifying CVO. IVUS is also used for sizing stents or balloons and during postintervention assessment.

### Can you tell us about your work in AV access for hemodialysis?

**Dr. Hull:** I have served as the Chief of Vascular and Interventional Radiology with Radiology Associates of Richmond since 1999. We cover eight hospitals and an outpatient vascular center in central Virginia. Our endovascular AV access patients are predominantly referrals by the dialysis centers and vascular surgeons. We see patients for vein mapping, problems with access, and interval 3-month screenings. Approximately 85% of our AV access patients have AV fistulas.

**Dr. de Graaf:** I work in a university hospital in The Netherlands and a large community hospital in Germany. I treat the majority of my dialysis patients in Maastricht, The Netherlands, where a large number of our patients with hemodialysis problems are referrals (especially those with central venous issues). A large majority of these cases are due to having a central catheter being implanted in the first place. So we try to get our catheter numbers as low as possible, approximately 5%. Native fistulas make up 60% of our initial cases, while 40% are AV grafts.

**Dr. Pavillard:** Today my primary work is in the hospital; however, I am in the process of opening an office-based lab with an ambulatory surgery center in the summer 2017. I conduct a substantial number of endovascular AV access procedures each month (approximately 60–75), and all are referrals from nephrologists. Native fistulas make up 75% of those procedures. Although used less often, the AV grafts and catheters require a lot more maintenance due to the foreign body aspect and greater exposure.

**Dr. Dolmatch:** Approximately 90% of my work is done in a hospital lab and the rest in an ambulatory surgical center. I perform approximately 30 AV access procedures per month (15 fistulas, 10 catheters, and five grafts). Referrals are primarily from nephrologists.

### How would you characterize your experience with IVUS as it relates to hemodialysis AV access?

**Dr. Pavillard:** My experience with IVUS developed over time. I started with the Pioneer Plus IVUS guided re-entry catheter (Philips Volcano), and then I began using the Visions PV .035 catheter (Philips Volcano) in aortic work. After seeing the value the images provided me, I took IVUS into the peripheral realm with the legs first and then into dialysis work in the arms. Today, 55% of my IVUS cases are hemodialysis AV access.

**Dr. de Graaf:** I have used IVUS increasingly since 2009, mainly in iliofemoral venous obstructions. In the beginning, it seemed somewhat difficult, but after just a couple of cases, you become familiar with it and quickly learn to appreciate the added information it provides. Three years ago, I started to use IVUS in AV access and did a lot of evaluations of stenosis in the cephalic arch and subclavian-innominate vein transition. It was clear to me that we saw more with IVUS than with angiography. This led to a better diagnosis and, accordingly, better patient outcomes. It was amazing to see stenosis looking completely resolved on angiography after percutaneous transluminal angioplasty (no signs of residual stenosis) while on IVUS, a clear obstruction was visible with trabeculations, intraluminal fibrotic strands, and/or dissections.

**Dr. Dolmatch:** I've used IVUS for 20 years, with early experience predominantly for peripheral artery disease. In my current practice, over the past 4 years, I've been using the Visions PV IVUS catheters for primarily venous problems and occasionally arterial. As an interventional radiologist, I'm comfortable with ultrasound and the information it affords. It is really not that hard to interpret. You can see the flow within the vessel, and you can see the vessel wall. The interface is what you need to see, and that's pretty easy to distinguish with IVUS. You just have to be comfortable with taking the catheter and moving it back and forth inside to really understand what the vessel wall is doing throughout.

**Dr. Hull:** I first started using IVUS in the early 2000s for carotid stents, endografts, and peripheral vascular disease—particularly during stenting and atherectomy procedures. IVUS is especially useful in the evaluation of CVO, specifically in the cephalic arch, the subclavian vein, and the brachiocephalic

vein. The cephalic arch and thoracic outlet segment of the subclavian vein are areas that cannot be easily visualized and are notorious for suboptimal results. IVUS is an important tool before and after balloon angioplasty and stent procedures.

### Is predialysis planning prevalent in your referral base?

**Dr. Pavillard:** The majority of our referrals are chronic kidney disease, stage 4 predialysis patients. They are referred by the nephrologists who do a lot of preoperative mapping with transcutaneous ultrasound, choose the best vessels, and perform the fistula creation. I follow afterwards, and in the event that there is inadequate maturation, I consider endovascular intervention to improve things. I want to minimize cases of further surgery for patients who would not tolerate it well.

The advantage is being able to establish a fistula well before the need for it. This prevents someone who is decompensated due to a more advanced kidney procedure from having to undergo a surgical procedure that they may not tolerate as well. With IVUS, it allows me to work on the fistulas and do as much as I can to help them mature before their need for access; this way, I can do it without the use of dye and potentially threatening and advancing their kidney disease.

**Dr. Hull:** Preplanning for early access creation to minimize catheter-based initiation of hemodialysis is a very important concept. A physical exam and Doppler ultrasound provide a good basis for selecting patients for AV fistula creation, which we do in the office-based lab. In the predialysis population, studying the central circulation without the use of iodinated contrast is an ideal use for IVUS.

### What is your experience with covered stents?

**Dr. Pavillard:** I primarily reserve the covered stents for a stenosis proximal to the access zone in lesions associated with tributaries that “steal” away from the main part of the fistula. I also use it on an outflow stenosis, primarily at a venous anastomosis with intimal hyperplasia. With IVUS, I measure and oversize by approximately 10% to 15% with respect to the diameter of the length or I extend proximally 2 mm beyond the lesion length.

### How do you know when the thrombus burden has been sufficiently reduced?

**Dr. de Graaf:** Residual thrombus is an obvious risk factor for early rethrombosis, which is why

preprocedural imaging is essential. I see much more with IVUS than I do with single or multiplanar angiography. Once the thrombus location and burden are identified with IVUS, accurate and complete thrombectomy can be performed.

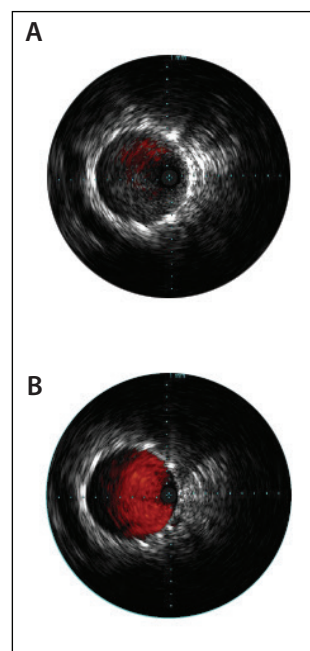
**Dr. Dolmatch:** If I am in doubt in an AV graft or fistula, I reach for IVUS. The central veins are where I can't really tell much of anything. I'm always struggling with how the central veins are, if they are extrinsically compressed, if there is stenosis or thrombus, or something else I just can't see. I find that IVUS is particularly useful in this region

because I can't use surface grayscale ultrasound.

Sizing for stent grafts in the central veins is particularly difficult because central veins don't typically have a round cross section. They can be quite eccentric. So if you see a vein that looks like it might be 16 mm in diameter on a venogram, it might be 16 mm in the way you're looking at it on a frontal film, but it might only be 7 mm front to back. I think understanding the geometry of things is really important, as well as the intrinsic versus extrinsic reasons for narrowing. That is where IVUS really has a lot of power, and I use it liberally in my thoracic CVO cases.

### For patients referred for high cannulation pressure, low flow, and/or insufficient Kt/V, how do you gauge completeness of therapy?

**Dr. de Graaf:** Principally, we use angiography. However, for the more central lesions in which multiplanar angiography may be more cumbersome, thorough evaluation with IVUS is typically added. I believe most patients coming back with an early recurrence were not optimally evaluated during the initial intervention. A recurrence within a month is



Courtesy of Dr. Pavillard.

**Figure 1. Example of ChromaFlo before and after thrombus removal. Extensive thrombus, minimal blood flow shown by ChromaFlo (A). Minimal residual thrombus increased blood flow (B).**

usually not due to reactive intimal hyperplasia, but rather incomplete treatment in the first place. With IVUS, we can better understand what we are looking at so we can tailor treatments. Irregular intraluminal fibrosis may best be treated with a stent (graft), while a smooth neointimal lesion may require a drug-coated balloon (DCB).

### How would you describe the utility of IVUS when interrogating peripheral elements of the access circuit versus the central veins?

**Dr. Pavillard:** I use it in all segments and will take it up to the aortic arch and bring it all the way back to the arterial system through the anastomosis and then interrogate the anastomosis itself (the conduit, including the access zone and the outflow, all the way up to the vena cava and right atrium).

**Dr. Hull:** IVUS is complementary to our Doppler ultrasound exam. For patients with fistula access but not yet on dialysis, I have used a combination of IVUS and Doppler ultrasound to guide and assess therapy in the peripheral portions of a fistula. IVUS provides a unique perspective on intimal hyperplasia versus mural thrombus. IVUS also provides unique information after intervention, showing micropseudoaneurysm and areas of disruption with or without extravasation. These morphologic changes that occur after balloon dilatation are likely to be important when using DCBs for the treatment of AV fistula stenosis.

### What developments will affect the creation, maturation, and maintenance of AV access circuits in the near future?

**Dr. Hull:** Technologies currently exist that enable the creation of percutaneous AV fistulas (not cleared for marketing in all geographies). These devices have been developed to decrease the morbidity, mortality, and costs associated with catheter-based hemodialysis by increasing early fistula placement and reducing the time required to secure a functional fistula in patients on catheter dialysis. Percutaneous fistula technologies have the potential to increase the pool of physicians qualified to create high-quality AV access fistulas.

The current high rate of failure for surgical fistulas to mature is an important driver for many new innovations addressing AV access maturation and maintenance, starting at the molecular level of intimal hyperplasia and working through the development of devices such as percutaneous grafts and bioengineered tissue grafts. DCBs have combined mechanical and pharmacologic technology to treat stenosis and restenosis of fistulas with some promising results.

**Dr. Dolmatch:** Three primary areas come to mind. First, vein preservation throughout the medical community for patients with chronic kidney disease. Second, is avoidance of catheters with early referral for fistula creation. Third, is ongoing development to determine if there are predictive factors to better assess whether a fistula will mature or not before it's created.

It's an exciting time for AV access. I have not seen so many novel approaches introduced in many years. This past year, 2016, marked the 50th anniversary of the AV fistula, and I would say that there has been very little advancement or improvement of the basic native fistula, a proven procedure that has stood the test of time. However, we are now seeing novel approaches that are in prospective randomized clinical trials. It's a very dynamic time right now. ■

Philips Volcano is committed to supporting customers new to our technology by providing a comprehensive medical education curriculum. From basic to advanced educational opportunities, we guide customers to clinical independence through a variety of learning forums that best meet their unique training needs.

Proctorships are available with Dr. Edward Pavillard for attending physicians interested in observing live cases and gaining deeper insight into the clinical evidence and data supporting the role of IVUS in hemodialysis arteriovenous access. Contact your local Philips Volcano representative for more information.